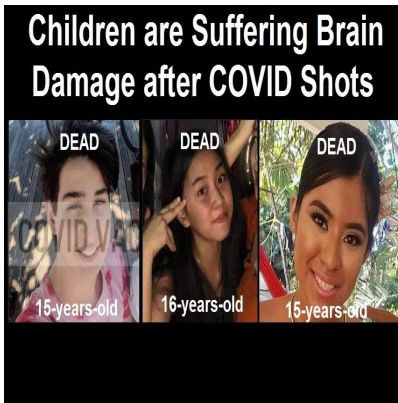



Cases of Brain Damage in Children Skyrocket Following COVID-19 Vaccines

Description

Weakened hearts, blood clots, and now you can add neurological brain damage to the list of side effects being reported in children following COVID-19 vaccinations.

In at least one case, one poor child developed all three conditions.

In a case study published earlier this month (May, 2022) in the Journal of Neuroimmunology, a 15-year-old girl developed encephalopathy, myocarditis, and thrombocytopenia simultaneously following the second dose of the Pfizer COVID-19 vaccine.

As billions of people are getting vaccinated, it is not surprising that vaccine-related adverse events are coming into focus and being reported in the scientific literature.

Here we report a case of COVID-19 mRNA Pfizer- BioNTech vaccine-associated encephalopathy, myocarditis, and thrombocytopenia following the second dose of vaccine which responded dramatically to methylprednisolone. ([Source.](#))

Neurological issues are common side effects of all childhood vaccines, and are often grouped under the label of "autism." There is a very clear correlation with increased vaccinations of children to rising rates of autism in the United States, even though the U.S. Government health agencies refuse to acknowledge any causal effect between the bloated childhood vaccine schedule and diagnoses of autism.

It is no surprise, therefore, that we are seeing similar reports following the deadly COVID-19 vaccines.

But how do reports of brain damage following COVID-19 vaccines compare to the rate of brain damage reported with all other vaccines administered for the previous 30 years before the roll-out of the COVID-19 experimental shots?

To develop a baseline, I chose to search VAERS (*Vaccine Adverse Events Reporting System*) for all cases reporting "encephalopathy" following vaccination.

“Encephalopathy” is a term for “any diffuse disease of the brain that alters brain function or structure.” ([Source.](#))

This term alone does not represent all the cases of neurological damage to the brain that are reported in VAERS, but it does give us a point of reference to compare cases reported after COVID-19 shots as compared to all other FDA-approved vaccines for the previous 30+ years.

And what I found was that there is a 2,000%+ increase in brain injuries being reported after COVID-19 shots.




Here are the results based on a search for “encephalopathy” symptoms after COVID-19 vaccines. ([Source.](#)) Notice the high rate of death among these cases of “encephalopathy.”

Search Results

From the 5/13/2022 release of VAERS data:

Found 1,092 cases where Vaccine is COVID19 and Symptom is encephalopathy

Table

 Event Outcome	Count	  Percent
Death	247	22.62%
Permanent Disability	80	7.33%
Office Visit	121	11.08%
Emergency Doctor/Room	384	35.16%
Hospitalized	895	81.96%
Hospitalized, Prolonged	5	0.46%
Recovered	233	21.34%
Birth Defect	1	0.09%
Life Threatening	142	13%
Not Serious	53	4.85%
TOTAL	† 2,161	† 197.89%
† Because some cases have multiple vaccinations and symptoms, a single case can account for multiple entries in this table. This is the reason why the Total Count is greater than 1092 (the number of cases found), and the Total Percentage is greater than 100.		

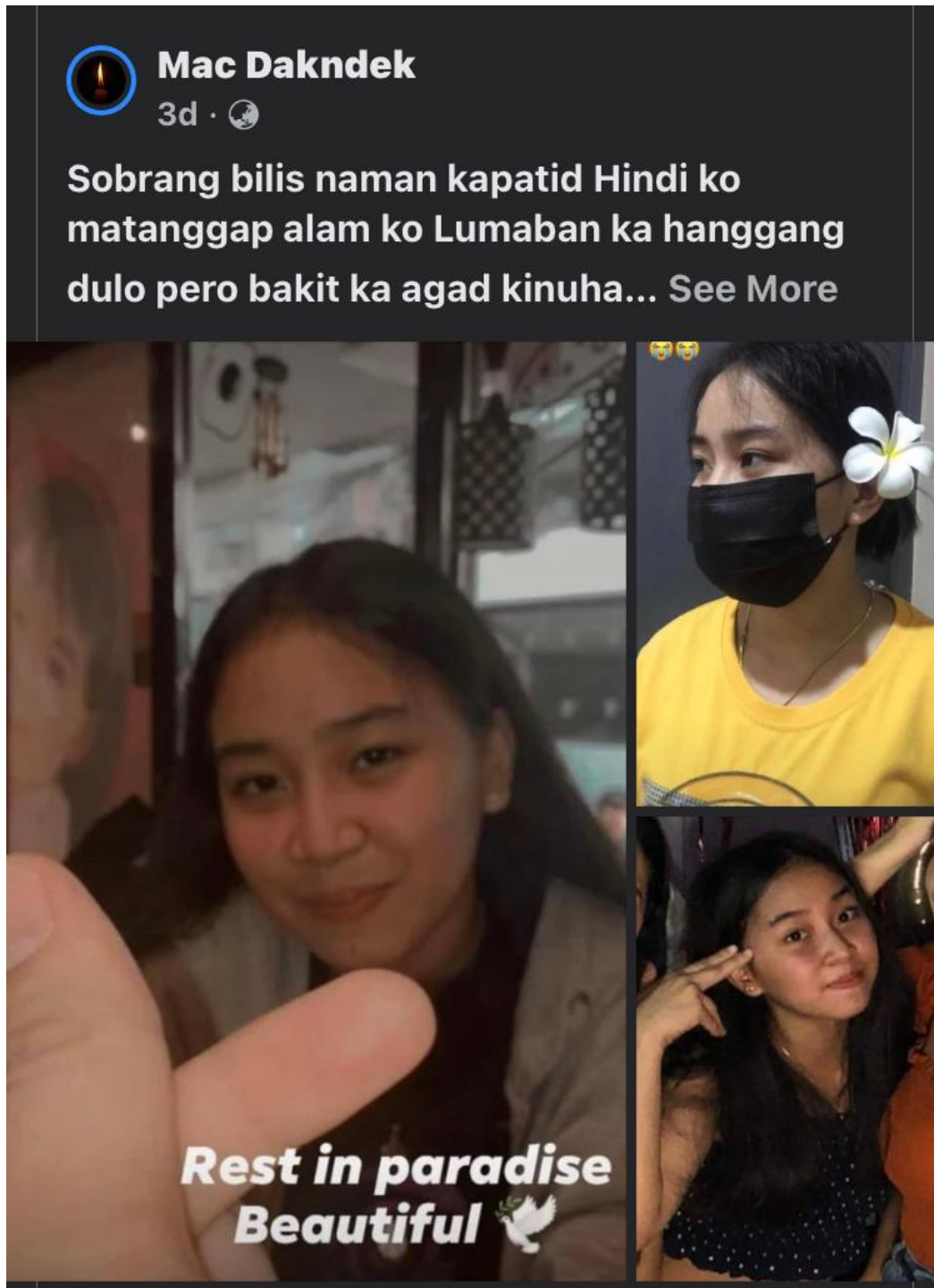This is the result from 17 months of COVID-19 vaccine distribution since December of 2020, when the vaccines were given emergency use authorization, which is over 64 cases per month.

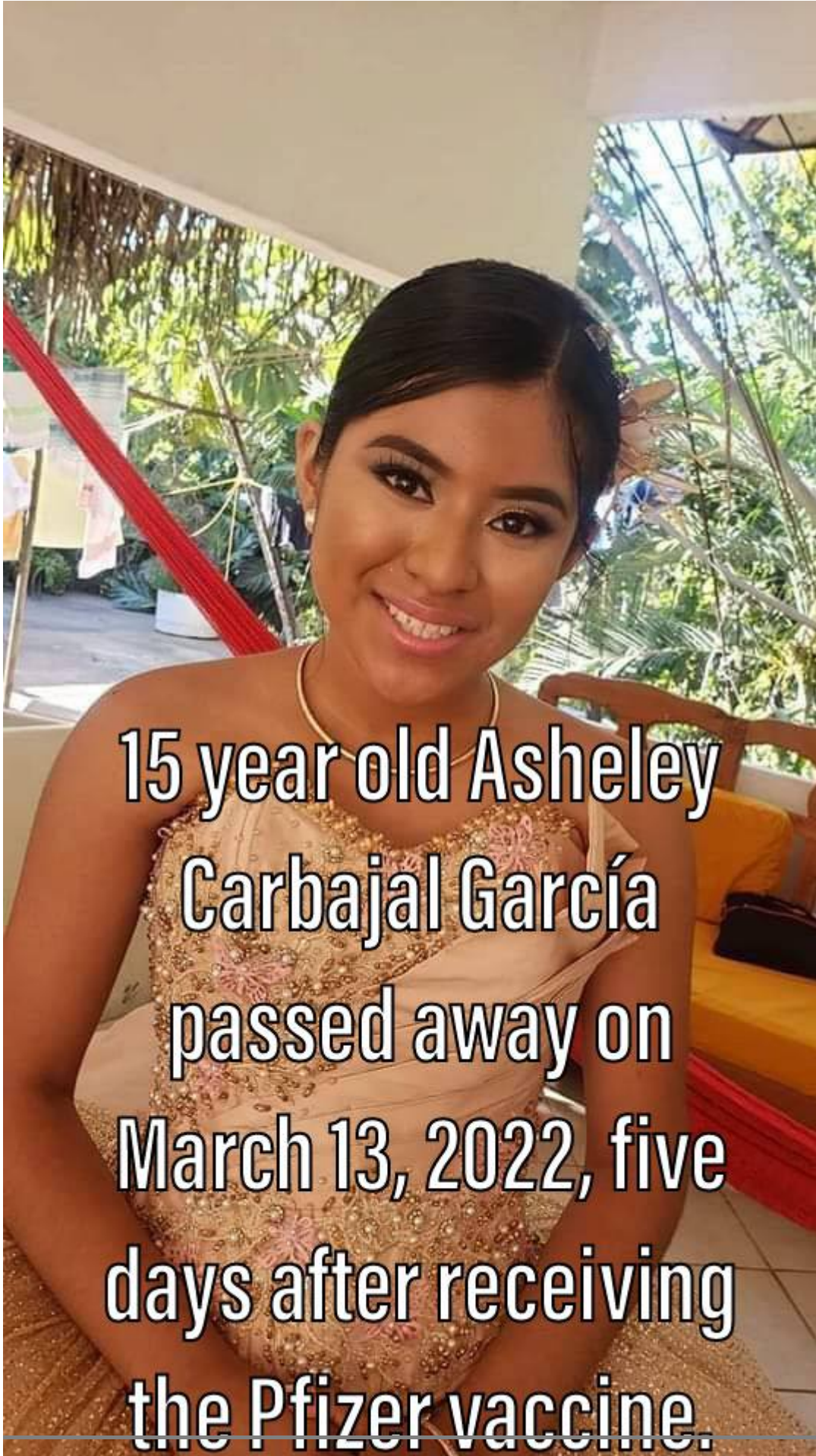By way of contrast, for the previous 30 years (360 months) before the COVID-19 vaccines started, there were 1,068 cases of “encephalopathy” reported after all other FDA-approved vaccines, an

average of less than 3 per month. ([Source.](#))

That is an increase of over 2000%.

Here are a few faces from some children who lost their lives due to brain damage because their parents forced them to get one of these shots, as reported on social media.







Marygrace Balasabas is with **Shannon ...**
A. Nuñez and 2 others.

April 27 at 6:48 AM · 🌐

To all of my friends.. We are begging for your kindhearted heart in behalf of my pamangkin TANYA (8 yrs old) who is currently confined due to ENCEPHALITIS after receiving her 2nd dose vaccine.

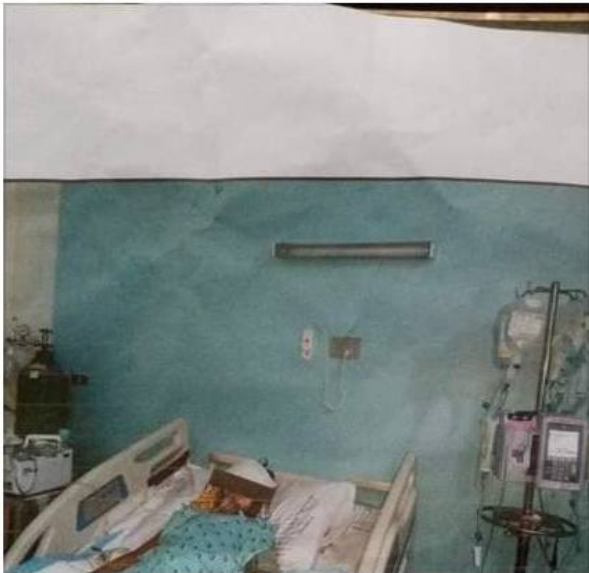
Still ongoing tests for the real cause of her disease. Your prayers is a big help and any small amount that she can use for her medication. Our ALMIGHTY LORD will return back for all your goodness., 🙏🙏🙏
🙏 Thank you all so much in advance.

You can send any amount on my:

☀️☀️ Gcash/09270456317

Rowena Nuñez

AGAIN THANK YOU SO MUCH and God bless you all and your Family.. 🙏🙏🙏





DANYLO

DANYLO ZINNECK NOBRE, 15 ANOS

EM 24/AGOSTO/2021
E 19/OUTUBRO/2021

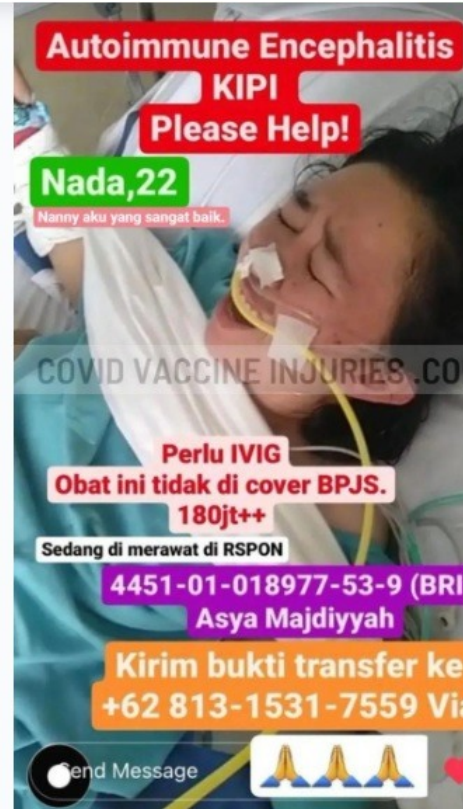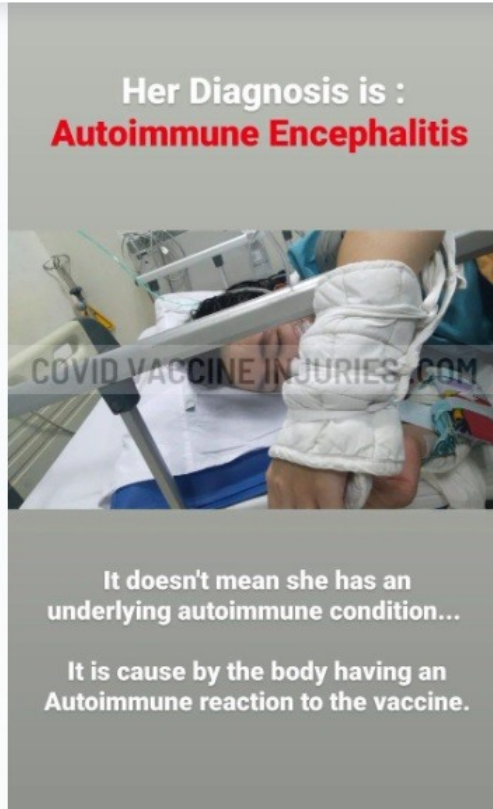
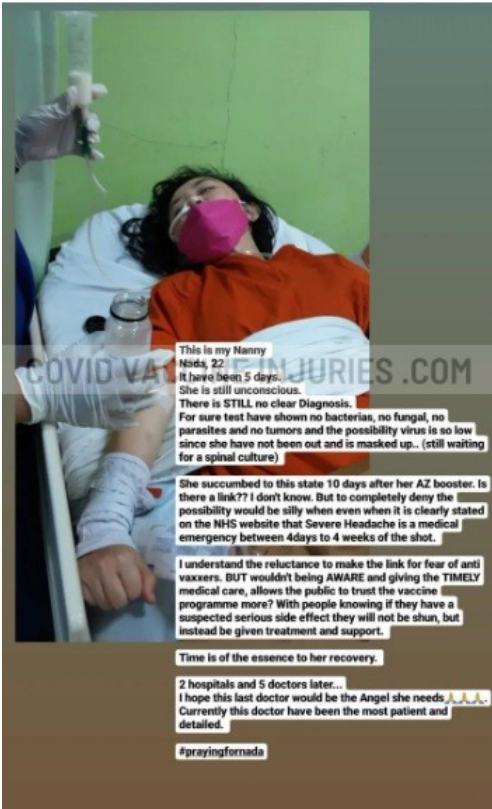EM 03/MARÇO/2022

PFIZERÓBITO

APÓS 18 DIAS DA SEGUNDA DOSE, COMEÇOU A SENTIR FADIGA, FRAQUEZA. DEPOIS, VISÃO TURVA. NO INÍCIO DE JANEIRO, SOFREU UMA CONVULSÃO, TEVE QUE SER ENTUBADO, COM DIFICULDADE DE DEGLUTIÇÃO, PARALISIA NOS MEMBROS SUPERIORES, E INFERIORES E NO DÍAFRAGMA. FEZ TRATAMENTO DE PLASMAFERESE, PORÉM SOFREU UM AVC HEMORRÁGICO, E POR FIM, MORTE ENCEFÁLICA.

ENCEFALITE AUTOIMUNE

Para reportar seu caso escreva para: oscasosraros@gmail.com / Instagram: [@OscasosRaros](https://www.instagram.com/OscasosRaros) / Telegram: [OscasosRaros](https://www.telegram.com/OscasosRaros)



*

First published on Jun2 2, 2022

All images in this article are from HIN

By Brian Shilhavy

Category

1. Crime-Justice-Terrorism-Corruption
2. Disasters-Crisis-Depopulation-Genocide
3. Health-Wellness-Healing-Nutrition & Fitness
4. Main
5. NWO-Deep State-Dictatorship-Tyranny

Date Created

June 2022